CLINICAL QUESTIONS EXTREME CURRENTS SYNDROME MIRIZZI

Abdurakhmanov D.Sh.[1], Yuldashev P.A.[2], Rakhmanov K.E.[3], Davlatov S.S.[4]
Email: Abdurakhmanov6108@scientifictext.ru

[1]Abdurakhmanov Diyor Shukurullaevich – Assistant;
[2]Yuldashev Parda Arzikulovich – Assistant;
[3]Rakhmanov Kosim Erdanovich - PhD, Associate Professor,
DEPARTMENT OF SURGICAL DISEASES № 1,
SAMARKAND STATE MEDICAL INSTITUTE,
SAMARKAND;
[4]Davlatov Salim Sulaimanovich - PhD, Associate Professor,
DEPARTMENT OF FACULTY AND HOSPITAL SURGERY, UROLOGY,
BUKHARA STATE MEDICAL INSTITUTE, BUKHARA,
REPUBLIC OF UZBEKISTAN

Abstract: *purpose of the study. Demonstrate two clinical observations of the unfavorable course of Mirizzi syndrome.*
Materials and methods. This work presents two clinical observations of the extreme courseMirizzi syndrome.
Results. In the first observation, the reactive course of Mirizzi I syndrome with a pronounced general systemic response of the body to endogenous infection was considered. In the second observation, data are considered that characterizethose who have a variant of the course of Mirizzi V syndrome b.
Conclusion. Timely diagnosis of Mirizzi syndrome and determination of the optimal method for furthertreatment may reduce the risk of intraoperative injury.
Keywords: *Mirizzi syndrome, Mirizzi syndrome type 5, complication of cholelithiasis, bilechangeable obstruction.*

КЛИНИЧЕСКИЕ ВОПРОСЫ ЭКСТРЕМАЛЬНОГО ТЕЧЕНИЯ СИНДРОМА МИРИЗЗИ

Абдурахманов Д.Ш.[1], Юлдашев П.А.[2], Рахманов К.Э.[3], Давлатов С.С.[4]

[1]Абдурахманов Диёр Шукуруллаевич – ассистент;
[2]Юлдашев Парда Арзикулович – ассистент;
[3]Рахманов Косим Эрданович – кандидат медицинских наук, доцент,
кафедра хирургических болезней № 1,
Самаркандский государственный медицинский институт,
г. Самарканд;
[4]Давлатов Салим Сулайманович – кандидат медицинских наук, доцент,
кафедра факультетской и госпитальной хирургии, урологии,
Бухарский государственный медицинский институт, г. Бухара,
Республика Узбекистан

Аннотация: *цель исследования. Продемонстрировать два клинических наблюдения неблагоприятного течения синдрома Миризzи.*
Материалы и методы. В настоящей работе представлены два клинических наблюдения экстремального течения синдрома Миризzи.
Результаты. В первом наблюдении рассмотрено реактивное течение синдрома Миризzи I с выраженной общей системной реакцией организма на эндогенную инфекцию. Во втором наблюдении рассмотрены данные, характеризующие вариант течения синдрома Миризzи V b.
Заключение. Своевременная диагностика синдрома Миризzи и определение оптимального метода дальнейшего лечения может уменьшить риск интраоперационных повреждений.
Ключевые слова: *синдром Миризzи, синдром Миризzи 5 тип, осложнение желчнокаменной болезни, желчнокаменная непроходимость.*

Introduction. Mirizzi syndrome (SM) is one of the most severe complications of cholelithiasis (GSD), which includes the formation of biliary and biliodigestive fistulas. SM occurs in 0.2–5.0% of patients [1,2,4,5]. In developed Western countries, the syndrome occurs in less than 1% of patients, in underdeveloped countries - from 4.7 to 5.7% [6]. Mortality in this disease is 11-14% [2,3,4]. Strictures of hepaticoholedochus and residual choledocholithiasis in the late postoperative period were observed in 13-14% of patients [2,3,4]. Type I CM implies compression of the bile duct by a gallstone wedged into the neck of the gallbladder or cystic duct. Type II consists of a cholecystobiliary fistula resulting from the erosion of the bile duct wall by gallstone. The fistula should include less than one third of the circumference of the bile duct. Type III consists of a cholecystobiliary

fistula involving up to two-thirds of the circumference of the bile duct. Type IV presents a cholecysto-biliary fistula with complete destruction of the bile duct wall with the gallbladder completely merging into one bile duct, forming a single structure without any recognizable landmarks between both bile tree structures. Type V includes a cholecysto-small bowel fistula along with any other type of CM [7,8]. Type Va is a cholecysto-small intestinal fistula without gallstone intestinal obstruction, Vb is a cholecysto-small intestinal fistula complicated by gallstone intestinal obstruction [6]. merging completely into one bile duct, forming a single structure without any recognizable landmarks between both structures of the bile tree. Type V includes a cholecysto-small bowel fistula along with any other type of CM [7,8]. Type Va is a cholecysto-small intestinal fistula without gallstone intestinal obstruction, Vb is a cholecysto-small intestinal fistula complicated by gallstone intestinal obstruction [6]. merging completely into one bile duct, forming a single structure without any recognizable landmarks between both structures of the bile tree. Type V includes a cholecysto-small bowel fistula along with any other type of CM [7,8]. Type Va is a cholecysto-small intestinal fistula without gallstone intestinal obstruction, Vb is a cholecysto-small intestinal fistula complicated by gallstone intestinal obstruction [6].

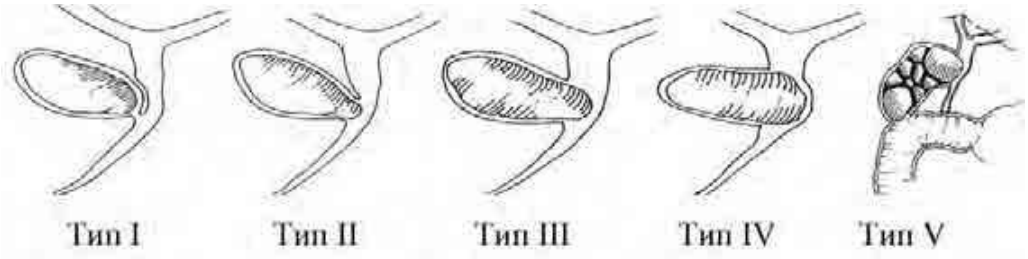

Fig. 1. Tipi of mirrizi syndrome

Clinical observation No. 1. Patient K. was admitted to the 1st clinic of SamMI on October 29, 2017 with a diagnosis of moderate viral hepatitis. Complaints of yellowness of the sclera, pruritus, dull epigastric pain, dark color urine. Sick more than 2 weeks, when skin itching appeared, yellowness of the sclera. Examined on an outpatient basis. In the blood, hyperbilirubinemia is 82.9 μmol / l due to the direct fraction, ALT is 212 units / l. Somatically healthy. Medicinal and allergic anamnesis are not burdened. Contact with infectious patients and blood transfusion denies. A condition of moderate severity. The skin is icteric, the sclera of the eyes are yellow. Vesicular breathing, no wheezing. Hemodynamics are stable. The abdomen is soft and painless. Blood test: total bilirubin - 62.3 μmol / l; ALT-179 units / l, ESR-32 mm / h. Preliminary diagnosis: "Viral hepatitis, icteric form?" Ultrasound of the abdominal cavity 05.11.17 - liver: visualization is indistinct, slightly increased, echogenicity is slightly increased. Increased echogenicity walls vessels in gate liver (vessels in the gate of the liver are not clearly differentiated). Portal vein visualization is indistinct, diameter 12 mm. Gallbladder: visualization is indistinct, contours are uneven. Kink in the upper third. Dimensions 102x44. The upper third is not clearly visualized. Content inhomogeneous, the neck is not differentiated. The walls are unevenly thickened. The echogenicity of the walls is increased. A displaced group of calculi with a maximum size of 18 mm is indistinctly located, and one fixed in the projection top thirds necks size 20 mm. Intrahepatic ducts not expanded, expanded equity ducts, choledoch not clearly differentiated. Pancreas: the contours are uneven, indistinct, the head is slightly enlarged, echogenicity is moderately increased, the structure is diffusely heterogeneous. The spleen is within normal limits. Diagnosis: “Cholelithiasis. Chronic calculous cholecystitis, exacerbation. Chronic pancreatitis, exacerbation. Obstructive jaundice. " 05.11.17 transferred to the surgical department for further treatment. After preoperative preparation and improvement of the patient's condition on 08.11.17, laparoscopy was performed. Found a gallbladder of purple color, the walls are thickened, tense. Puncture performed - from the lumen evacuated near 100 ml of light liquid, no bile. In the area of the neck is determined by the cartilaginous density of the infiltrate, the walls of the stomach and duodenum (duodenum) are tightly adhered to the neck of the gallbladder, hepato-duodenal ligament. Conversion completed. Palpation in the area of the neck of the gallbladder, the gate of the liver is determined by a dense, little displaceable education near ten cm diameter. The antrum of the stomach and duodenum are involved in the infiltrate. In the lumen of the bladder, multiple calculi about 0.5 cm in diameter are palpated, the walls of the gallbladder are cartilaginous, and purple in color. The neck of the gallbladder is tightly adhered to the wall of the duodenum. Acutely, the intestine is separated from the wall of the gallbladder. During dissection of adhesions, the intestinal wall was opened, the defect was sutured with a two-row continuous suture. A probe was introduced into the horizontal branch of the duodenum. Gall bladder highlighted of infiltration. In the projection of the bifurcation of the ducts, a round, dense formation of about 3.0 cm in diameter is determined by palpation. Isolation of elements of the liver gate is impossible due to the pronounced density of tissues, a high risk of damage to the main structures of the liver gate. Cholecystectomy from the cervix. Hemostasis. Drainage to the operation area. Layered sutures on the wound. Diagnosis after surgery: "ZhKB, empyema of the gallbladder, CM I, cancer of the gallbladder, liver hilus, tumor Klatskina from germination in wall of KDP (?) ". IN in the postoperative period from 09.11.17 to 10.11.17 a state of moderate severity. Complaints on pain in areas postoperative suture, in the abdomen on the

right, shortness of breath. Hemodynamics are stable, the tongue is clean, moist, the abdomen is symmetrical, swollen, soft, painful in the area of the postoperative wound. The drainage is serous-hemorrhagic. Indicators of blood tests are within normal limits, with the exception of hyper-transaminasemia (ALT - 137 units / l; AsAT - 98 units / l). 11.11.17 - serious condition, pulse 103 beats / min., NPV 27, blood pressure 110/60 mm Hg. Art. Against the background of ongoing therapy without significant positive dynamics, hemodynamics are unstable. On a chest x-ray, the dome of the diaphragm is high on the right. Heart sounds are muffled, rhythmic. Tongue dry, clean. On the nasogastric tube - a light cloudy discharge. The dressings are dry, in the area of the drainage the dressing is slightly soaked with discharge with an admixture of bile. Near the drainage from the subcutaneous tissue, when pressed, a discharge of yellow color comes in, with an intestinal odor. The discharge is light along the drain. Considering the patient's condition, the failure of the duodenal sutures was not excluded. The patient was transferred to the ICU. With ultrasound: fluid in the right subhepatic space is determined, the intestines are moderately swollen, sluggish peristalsis. There are signs of incipient phlegmon of the anterior abdominal wall, diffuse peritonitis. Blood test 11.11.17: Ht –37.1; platelets - 137x109; leukocytes - 1.5 x109; ESR - 37 mm / h; urea - 15.9 mmol / l; creatinine - 194.2 μmol / l; total bilirubin - 19.8 μmol / l; ALT - 107 units / l, AST - 76 units / l. General urine analysis 11.11.17 - protein 1.0, erythrocytes 4–8, hyaline cylinders 3–5, bacteria +. 11.11.17 when viewed at 17.00: pulse - 130, NPV - 22, CVP - 50 mm water column, BP - 98/60, Sp02–92%. Temperature - 36.7. The patient's condition was assessed as severe, unstable, caused by SIRS, severe sepsis, multiple organ failure syndrome against the background of the underlying disease and the postoperative period, secondary water-electrolyte and metabolic disorders. 11.11.17 an emergency operation was performed: relaparotomy, resection of the pyloric stomach, with separation of the duodenum, gastroenteroanastomosis end to side, enteroenteroanastomosis side to side, sanitation, drainage of the abdominal cavity, drainage of the fiber of the anterior abdominal wall. Diagnosis: Inconsistency of the duodenal seams, diffuse biliary peritonitis, phlegmon of the anterior abdominal wall. 11/12/17 - the condition is extremely serious, blood pressure is not determined, pulse 128 beats / min., Temperature 39.5. A state with negative dynamics (progression of cardiovascular, renal failure, due to the course of refractory septic shock). Mechanical ventilation. Medication sleep (GHB). Febrile fever (antipyretics are ineffective). Hemorrhagic discharge along the drains. The abdomen is not swollen, soft. The dressing is dry. Peristalsis is not heard. There is no urination through the catheter (against the background of saluretic stimulation). AT 02.

Final clinical diagnosis: Cholelithiasis. Empyema of the gallbladder. Mirizzi's syndrome I. Gallbladder cancer (?). Cancer of the liver hilum (?). Klatskin's tumor with germination into the wall of the 12th intestine (?). Inconsistency of the sutures of the duodenum, diffuse biliary peritonitis, phlegmon of the anterior abdominal wall. Autopsy revealed signs of septic shock, acute cardiovascular failure.

The observation considered the acute course of the formation of a biliodigestive fistula with a pronounced general systemic reaction of the body to endogenous infection.

In the second observation, we studied the features characterizing the variant of the flow of the SM Vb. Patient Ch., 72 years old, was admitted to the emergency room of the 1st clinic of SamMI on 20.07.18 with complaints of dull pain between the shoulder blades, which appeared 07/11/18 after an error in the diet. From 2010 to 2017, the patient was treated on an outpatient basis for ischemic heart disease, grade II hypertension, atherosclerotic cardiosclerosis. In 2015, an ultrasound scan revealed gallstone disease, chronic calculous cholecystitis, without exacerbation. Ultrasound of the abdominal cavity on admission: signs of chronic pancreatitis, cholelithiasis. Plain X-ray of the abdominal cavity: there is no free gas and liquid in the abdominal cavity. Blood test: leukocytosis (11.3 x 109), other indicators are within normal limits. Urine analysis: specific gravity - 1030, protein - 0.2 g / l, leukocytes 6-10 in the field of view, er - 0. Indications for hospitalization were not identified. 07/21/18 re-delivered to the emergency room of the city hospital and hospitalized with a diagnosis of cholelithiasis. Acute cholecystitis ". At the time of admission, the condition is of moderate severity, complaints of constant pain in the epigastrium, right hypochondrium, nausea, vomiting. The skin is of normal color and moisture, there is no icterus of the sclera. Pulse 80 beats / min. The abdomen is soft, not swollen, painful in the epigastrium. The gallbladder is undetectable. Ortner's symptom is indistinct. Plain X-ray of the abdominal cavity: liquid levels, no free gas. Gallbladder calculus. Conservative therapy was prescribed. Abdominal ultrasound (07/23/12): liver, pancreas, spleen, kidneys - no features. The gallbladder is 8.6x3.9 cm, the walls are 0.4 cm, infiltrated. In the cavity there is thick bile, multiple calculi up to 2.8 cm. A hypoechoic formation of 2.7x2.0 cm is adjacent to the bladder neck - an abscess? The patient is given barium. On Rg-graphy of the abdominal cavity after 5 hours, the filling with barium of the gallbladder, common bile duct, stomach is determined. Partially barium enters the small intestine in small quantities, there is a difference in the diameter of the intestine at the level of the vertical part of the duodenum. Diagnosis “Cholelithiasis. High small intestinal gallstone obstruction. " Emergency operation 07/24/12: under the ETN made an upper-median laparotomy. The gallbladder is undetectable. No effusion. There is a dense scar tissue infiltrate between the right lobe of the liver and the duodenum. There are no signs of inflammation. In the vertical branch of the duodenum, a dense calculus measuring 5x3.5 cm is determined. Acute high small intestinal gallstone obstructive obstruction is diagnosed. Gastrotomy in the antrum of the stomach. An attempt was made to displace the stone into the stomach. With

multiple attempts, it failed. Then an attempt was made to displace the stone into the small intestine, but in the area of the Treitz ligament, due to a discrepancy between the diameter of the intestine and the stone, this was not possible. The deserosed area of the initial part of the jejunum 1–2 cm was sutured with gray-serous sutures. Again, the stone is displaced proximally. After mobilization of the duodenum according to Kocher, with great technical difficulties due to the large size of the stone, it was possible to remove the stone from the gastrotomy opening with a clamp. Revision of the duodenum in the upper third of its vertical branch revealed a defect of the lateral wall 1.5–2 cm in diameter. With technical difficulties, the duodenal defect was sutured with a double-row suture. Taking into account the fact of damage to the duodenum, after suturing the gastrotomy opening, a posterior colic gastroenteroanastomosis with Brown's entero-enteroanastomosis was formed. At the end of the operation, a scanty leakage of bile was revealed in the area of the supposed internal vesico-intestinal fistula. It is technically impossible to establish the source. Placed drains to the place of bile leakage, along the right lateral canal and into the small pelvis. Layered suture of the wound. Diagnosis: Cholelithiasis. Mirizzi syndrome Vb. Acute gallstone small bowel obstruction. After the operation, the patient was transferred to the Department of Anesthesiology and Reanimation (OAR). In the postoperative period, antibacterial and infusion therapy was carried out. From 25.07.18 to 29.07.18, the general condition of moderate severity, stable. Complaints of moderate pain in the area of postoperative wounds. When dressing - a median wound, the bandage is blue-green in places, a scanty serous effusion was discharged along the drains. The condition is regarded as a developing biliary fistula. From 30.07.18 to 03.08.18 with daily examination: complaints of moderate pain in the postoperative area, the condition is severe, stable. On 07/31/18, a small amount of pus-like discharge from the small pelvis appeared around the drainage. A suture was removed in the middle third of the midline wound. Up to 20 ml of hemorrhagic fluid was released. The probe revealed a defect in the aponeurosis - a fixed eventration. Through the upper drainage - from the duodenum, cloudy, with a hemorrhagic component, discharge, up to 100 ml / day. 08/03/18 - 08/10/18 - improvement of the condition. Abdominal pains have decreased. Condition of moderate severity. Drainage from the duodenum functions - up to 350 ml / day. The drainage from the small pelvis is removed. The dressings are clean, dry, postoperative wound without signs of inflammation. There was no chair. The gases escape. 08/12/18, there was vomiting after eating. The general condition is serious. Through a gastric tube, the stomach was washed, up to 500 ml of stagnant contents were removed. The catheter removed 100 ml of blood-stained urine. The patient has hematuria of unknown origin. 08/13/18 the patient's condition is serious, conscious, adequate, the skin is grayish, blood pressure 100/160 mm Hg. Art., pulse 80 beats / min.; CBD negative; the belly is soft. Intestinal discharge enters through the duodenal fistula. In clinical and biochemical parameters, leukocytosis with neutrophilic shift, hypoproteinemia, moderate hyperkalemia, hyponatremia, azotemia. On August 15, 2018, the patient underwent laser blood irradiation, without complications. FEGS 15.08.18 .: through gastroenteroanastomosis (edematous with fibrin deposits), the apparatus is inserted 25 cm into the jejunum. The conductor was abandoned. 08/15/18 at 18: 00 the patient suffered cardiac arrest due to increasing multiple organ failure. Transferred to mechanical ventilation. Death was pronounced on 15.08.18 at 18:30. Diagnosis. The underlying disease. Cholelithiasis. Mirizzi syndrome Vb. The state of post-aparotomy, gastrotomy, removal of a stone from the duodenum, the formation of gastroenteroanastomosis from 24.07.18. Concomitant diseases. Ischemic heart disease. Atherosclerotic cardiosclerosis. Atrial fibrillation, permanent form. CH II. Complication of the underlying disease. External duodenal fistula. TELA. Progressive multiple organ failure: cardiovascular, hepatic, renal failure. gastrotomy, removal of a stone from the duodenum, the formation of gastroenteroanastomosis from 24.07.18, Concomitant diseases. Ischemic heart disease. Atherosclerotic cardiosclerosis. Atrial fibrillation, permanent form. CH II. Complication of the underlying disease. External duodenal fistula. TELA. Progressive multiple organ failure: cardiovascular, hepatic, renal failure. gastrotomy, removal of a stone from the duodenum, the formation of gastroenteroanastomosis from 24.07.18, Concomitant diseases. Ischemic heart disease. Atherosclerotic cardiosclerosis. Atrial fibrillation, permanent form. CH II. Complication of the underlying disease. External duodenal fistula. TELA. Progressive multiple organ failure: cardiovascular, hepatic, renal failure.

Conclusion

In both cases presented, an extreme course of Mirizzi's syndrome was demonstrated, fatal.

References / Список литературы

1. *Davlatov S.S., Rakhmanov K.E.* Tactics of managing patients with bile leakage after cholecystectomy // Problems of Science and Education, 2020. № 13 (97).
2. *Rahmanov Kosim DS, Laylo R.* Improvement of surgical treatment of intraoperative injuries of magistral bile duct // The 17th International medical congress of students and young scientists. Ternopol., 2013. S. 22-24.
3. *Kurbaniyazov Z.B., Rakhmatova L.T., Zainiev A.F., Rakhmanov K.E., Saidmuradov K.B., Davlatov S.S. & Abdurakhmanov D.Sh.* (2013). Surgical approach to the treatment of patients with "fresh" injuries of the main bile ducts. Academic Journal of Western Siberia. 9 (2). 14-15.

4. *Rizaev J.A., Rizaev E.A., Akhmadaliev N.N., Abdurakhmanov D.Sh.* (2020). Modern perspective on the problem: a new approach to the treatment of Covid-19 Indian Journal of Forensic Medicine and Toxicology. 14 (4).
5. *Abdurakhmanov D.Sh. & Olimdzhonzoda H.L.* (2020). Evolution of diagnostic methods and surgical treatment of liver echinococcosis. achievements of science and education 16 (70).